

ORIGINAL RESEARCH

# Conventional radiographic analysis of facet joint and condylar erosion in patients at the UCSG. Prevalence study

## *Análisis radiográfico convencional de fasetamientos y erosiones condilares en pacientes de la UCSG. Estudio de prevalencia*

Christian Steven Ávila Aguirre<sup>1</sup>. Dennisse Fernanda Diaz Rojas<sup>2</sup>. Nicole Fabiana Diaz Rojas<sup>3</sup>

<sup>1</sup> Dentist. Universidad Católica de Santiago de Guayaquil. <https://orcid.org/0009-0006-5910-1836>

<sup>2</sup> Specialist in Dental Radiology and Imaging. Master's Degree in Health Services Management. Professor, Universidad Católica de Santiago de Guayaquil. <https://orcid.org/0000-0002-1474-0232>

<sup>3</sup> Dentist. Universidad Católica de Santiago de Guayaquil. <https://orcid.org/0009-0009-3273-5590>

Correspondence to: [dennisse.diaz@cu.ucsg.edu.ec](mailto:dennisse.diaz@cu.ucsg.edu.ec)

Received: 12/12/2025 Accepted: 02/10/2026

### ABSTRACT

Introduction: The degenerative alterations commonly found in the TMJ include condylar flattening and erosion of its articular surface, changes that can be observed in imaging studies. Objective: To determine the prevalence of condylar facets and erosions observed in panoramic radiographs of patients treated at the dental clinic of the Catholic University of Santiago de Guayaquil during the B – 2024 term (January-December). Materials and Methods: A cross-sectional descriptive and analytical study with a qualitative-quantitative approach was conducted. The final sample size consisted of 274 digital panoramic radiographs obtained from the UCSG Radiology Laboratory, after obtaining prior permission. Results: The findings revealed that only 16.8% (n = 15) of the evaluated samples presented condylar erosions. When evaluating facets, it was observed that 41.6% exhibited bilateral condylar facets. Women presented higher percentages of both erosions and facets compared to men (p > 0.05). The group with condylar facets had a mean age of 34.45 years, while the group with condylar erosions had a mean age of 38.48 years. Conclusion: This study found that condylar facets, whether unilateral or bilateral, were significantly more frequent in the study population than condylar erosions. The results demonstrated a complete absence of coexistence between both evaluated conditions, suggesting a statistically significant inverse relationship.

Keywords: Faceting. Erosion. Degenerative alterations. Temporomandibular Disorders, mandibular condyle

### RESUMEN

Introducción: Las alteraciones degenerativas que se encuentran comúnmente en la ATM comprenden el aplanamiento del cóndilo y la erosión de su cara articular, cambios que pueden observarse en las imágenes. Objetivo: Determinar la prevalencia de fasetamientos y erosiones condilares observadas en radiografías panorámicas de pacientes atendidos en la clínica odontológica de la Universidad Católica de Santiago de Guayaquil durante el periodo B – 2024 (Enero-Diciembre). Materiales y métodos: Se realizó un estudio transversal, de diseño descriptivo y analítico, de enfoque cuali-cuantitativos. El tamaño de la muestra final fue de 274 radiografías panorámicas digitales obtenidas del Laboratorio Radiológico de la UCSG, previo permiso. Resultados: Los resultados obtenidos reportan que solo el 16,8% (n = 15) de las muestras evaluadas presentaron erosiones condilares. Al evaluar los fasetamientos, se observó que el 41,6% presentaron fasetamientos en ambos cóndilos mandibulares (bilaterales). Las mujeres presentaron porcentajes mayores de erosiones y fasetamientos en comparación con los hombres (p > 0,05). El grupo de pacientes con presencia de fasetamientos condilares presentaron una media de edad de 34,45 años, el grupo de fasetamientos condilares presentaron una media de 38,48 años. Conclusión: En el presente estudio se encontró que los fasetamientos condilares, ya sea unilateral o bilateral, fue significativamente más frecuente en la población de estudio que las erosiones condilares. Los resultados evidenciaron una ausencia total de convivencia entre ambas condiciones evaluadas, sugiriendo una relación inversa estadísticamente significativa.

Palabras Clave: Fasetamiento, Erosión, Alteraciones degenerativas, Trastornos temporomandibulares, cóndilo mandibular.

**INTRODUCTION**

The temporomandibular joint (TMJ) is one of the most complex joints in the human body and is essential for performing masticatory, swallowing, and speech functions. It connects the mandibular condyle with the fossa of the temporal bone, and an articular disc facilitates its movement. It allows both rotation and translation, making it susceptible to various structural and functional changes due to the loads it supports.<sup>1 2</sup>

Temporomandibular disorders (TMD) include morphoanatomical and myofunctional alterations of the masticatory muscles, which are more prevalent in women. They are associated with symptoms such as pain, clicking, and limited or deviated mandibular movement, significantly affecting patients' quality of life.<sup>1 3 4</sup> Common degenerative alterations in the TMJ include condylar flattening (facet formation) and erosion, associated with visible wear signs on imaging. These are frequent in temporomandibular osteoarthritis (OA), an inflammatory disease that causes degenerative changes on joint surfaces without bone regeneration, impairing function and causing pain.<sup>4 2</sup>

Condylar erosion affects cartilage, cortical bone, and subcortical bone, manifesting with pain and functional limitation. These alterations, associated with the condition of the articular disc, aggravate symptoms and complicate the clinical picture in young patients, affecting their growth and dentofacial morphology, in addition to reducing mandibular functional capacity.<sup>1 5</sup> Condylar flattening, in turn, is characterized by the loss of its natural convexity. It may be anatomical, without significant changes in bone structure, or abnormal, accompanied by modifications in the cortical bone.<sup>6 7</sup> The study of degenerative changes in the TMJ can be carried out using radiographic techniques such as computed tomography and panoramic radiography. Panoramic radiography is recommended for identifying bony alterations of the condyle and is especially useful in patients with trismus, trauma, or financial limitations preventing access to tomography or magnetic resonance imaging.<sup>1 5 6</sup>

Erosive alterations of the TMJ, such as condylar erosion and flattening, present significant challenges for dental diagnosis and management, as they may generate symptoms such as pain, mandibular deviation, and joint sounds, among others, highlighting the need for proper evaluation and treatment.<sup>5 7</sup> Based on the reviewed background, the objective of this study was to determine the prevalence of condylar flattening and erosions observed in panoramic radiographs of patients treated at the dental clinic of the Universidad Católica de Santiago de Guayaquil during Period B – 2024.

**MATERIALS AND METHODS**

A cross-sectional study was conducted with a descriptive and analytical design, and a qualitative-quantitative approach. Sample size calculation was performed using Epilnfo (Population size: 967 panoramic radiographs; Confidence level: 95%; Frequency: 50%; Margin of error: 5%). The sample consisted of radiographs from patients aged between 18 and 69 years. The final sample size was 274 digital panoramic radiographs obtained from the Radiology UCSG Laboratory, collected from January to December 2024.

*Data Collection:* Before data collection, permission was requested to access radiographic records. All radiographs showing projection of the ascending ramus of the mandible and the entire condylar contour without image superimposition were included. Radiographs with blurred, distorted, or low-quality images were excluded, as well as radiographs of patients with a history of reconstructive surgery. A visual analysis was performed on each radiograph, and findings were recorded on a data collection form. The presence or absence of condylar flattening and erosions was recorded, in addition to age and sex. *Statistical Analysis:* Variables were coded in Microsoft Excel for tabulation. Descriptive statistics were used for general data interpretation. The following tests were applied: Chi-square, Fisher–Freeman–Halton exact test, Shapiro–Wilk, and Mann–Whitney U test.

**RESULTS**

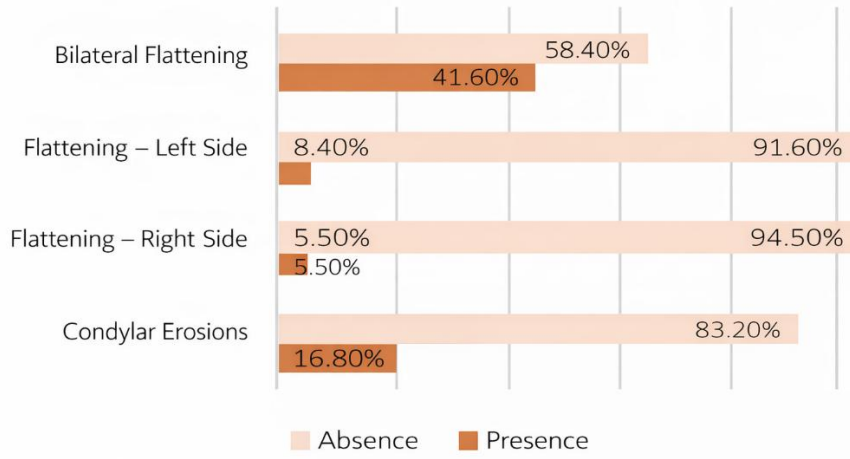
The sample consisted of radiographs from patients aged between 18 and 69 years, with a mean age of 33.79 (SD: 11.659). Regarding sex, women predominated in the sample, representing 72.6% of the evaluated radiographs (Table 1).

*Table 1. Demographic Characterization of the Study Population*

	N	%	Mean	Min	Max	SD
Age	274	100	33.79	18	69	11.659
<b>Sex</b>			<b>N</b>	<b>%</b>		
Female	199	72.60%				
Male	75	27.40%				

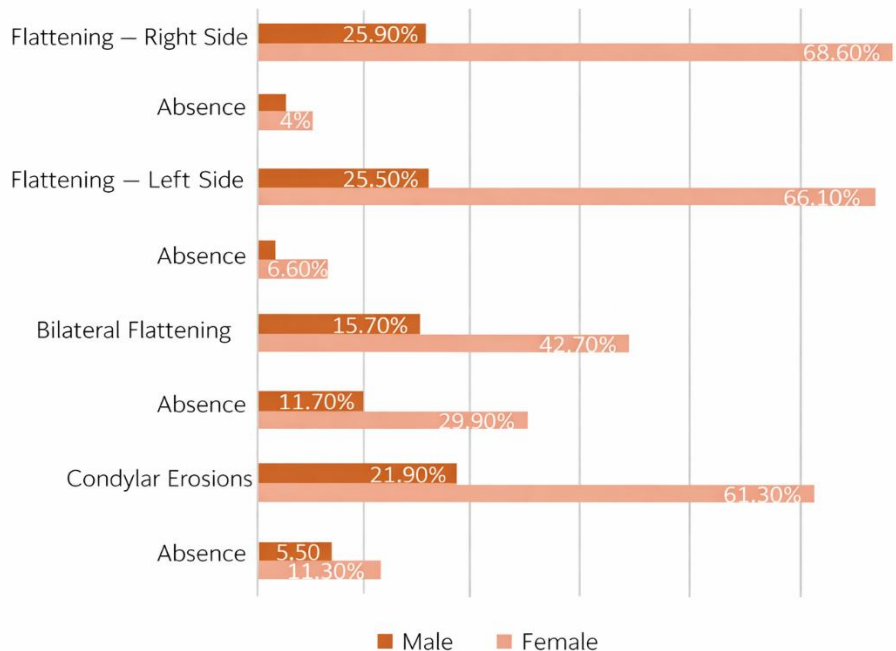
The results show that only 16.8% (n = 15) of the evaluated samples presented condylar erosions (Figure 1). When assessing flattening, it was observed that 41.6% presented flattening in both mandibular condyles (bilateral). Although in lower proportion, panoramic radiographs were also observed in patients presenting condylar flattening only on the right side and others only on the left side (Figure 1). No case with flattening presented condylar erosions and vice versa. The obtained results suggest a statistically significant inverse relationship ( $p < 0.001$ ).

Figure 1. Prevalence of condylar flattening and erosions in the study population.

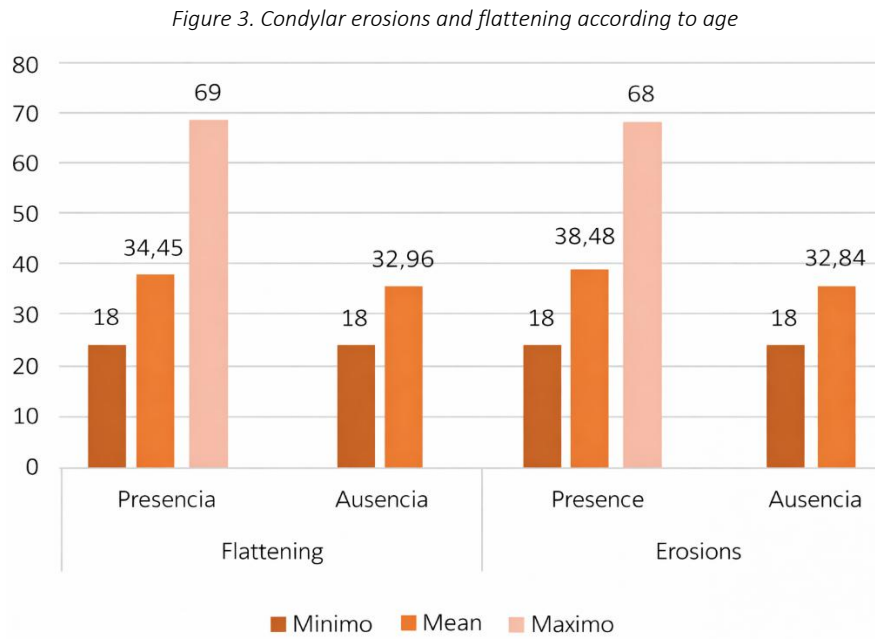


Regarding percentage distribution by sex, it was observed that within the group presenting condylar erosions, the highest percentage corresponded to women, at 11.3% ( $p = 0.383$ ). Within the group presenting flattening, women also predominated, with 29.9% bilateral ( $p = 0.827$ ), 6.6% left side ( $p = 0.527$ ), and 4% right side ( $p = 1.000$ ) (Figure 2).

Figure 2. Condylar erosions and flattening according to sex



It was observed that the group presenting condylar flattening—whether on the left side, right side, or bilaterally—had a mean age of 34.45 years, with a minimum of 18 and a maximum of 69 (SD: 12.141) (Figure 3). Regarding condylar erosions, the group presenting erosions had a mean age of 38.48 years, suggesting a slightly older age in this group, with a minimum of 18 and a maximum of 68 (SD: 12.053) (Figure 3).



The Shapiro–Wilk normality test was used. The results showed a significance value less than 0.05 ( $p < 0.001$ ), indicating that the evaluated data do not follow a normal distribution. Due to the non-normal distribution of the data, the Mann–Whitney U test was applied (Table 2). No statistically significant differences were found between patients with and without flattening and age ( $p = 0.431$ ). Regarding condylar erosions, a p-value of 0.001 was obtained, indicating significant age differences between patients with and without condylar erosions (Table 2).

*Table 2. Shapiro–Wilk Normality Test – Mann–Whitney U Test for Independent Samples*

Shapiro-Wilk			
	Statistic	gl	Sig.
Erosions	0,925	274	< 0,001
Flattening	0,451	274	< 0,001
Independent Samples Mann–Whitney U			
		N	274
Age	Condylar Erosions	U M W	3656,5
		Test Statistic	-3,241
		Sig.	0,001
Age	Flattening	N	274
		U M W	8759,5
		Test Statistic	-0,787
		Sig.	0,431

**DISCUSSION**

In a study conducted by Emshoff R et al.5 (2021), a high percentage of condylar erosions was found, accounting for 40.3% of their study sample. In contrast, in the present study, the absence of condylar erosions predominated, while condylar erosions were observed less frequently, comprising 16.9% of the sample.

Oliveira D et al.8 (2024), on the other hand, evaluated morphological changes of the condyle in patients with Angle Class II malocclusion. These authors reported that 59% of the sample presented flattening, followed by 31% with condylar erosions. These results contrast with those observed in this study, where minimal percentages of patients showed the presence of condylar erosions and flattening in the studied sample.

In another study, Arayasantiparb R et al.9 (2020), evaluated the radiographic characteristics of patients who had undergone Cone Beam Computed Tomography scans at a dental clinic in Thailand, where they observed that condylar flattening predominated at 89.4%. Other

authors, such as Jeon K et al.<sup>10</sup> (2021), reported low percentages of these anomalies, with 7% flattening and 7.3% condylar erosions in their study population.

Regarding flattening, Kilic S et al.<sup>11</sup> (2015), reported that 41% of the evaluated patients presented bilateral condylar flattening and 35% unilateral flattening. These findings partially coincide with those reported in this study, where 41.6% of cases presented bilateral condylar flattening. Meanwhile, Rodríguez Y, et al.<sup>12</sup> (2020) reported higher percentages; through panoramic radiographs, they observed that 78.4% of their sample presented flattening in the right condyle and 79.3% in the left condyle. In contrast, in this study, only 8.4% presented flattening on the left side and only 5.5% on the right side.

Bae et al.<sup>13</sup> (2017) found that the presence of both condylar erosions and flattening was the most frequently observed combination in their sample (12.7%). Jung et al.<sup>14</sup> (2022) also reported a slightly lower percentage of patients presenting this combination (condylar erosions and flattening), accounting for only 9.58% of the sample. Unlike these findings, in the present study, none of the evaluated cases presented a combination of these anomalies. Differences in craniofacial size, bite force, and masticatory muscle strength may influence the structural and functional characteristics of the temporomandibular joint. Several studies have reported a higher prevalence of temporomandibular disorders in female patients, as well as in patients with skeletal Class II.<sup>15</sup>

Gharge NR et al.<sup>1</sup> (2020) evaluated the temporomandibular joints and observed minority percentages in both sexes. Only 14% of the evaluated women presented condylar erosions, followed by 11% of men who also presented this pathology. In the present study, a similar percentage distribution was observed, where 11.30% of women presented condylar erosions. Regarding men, a slightly lower percentage than that reported by the authors was observed (5.5%).

Pearson's Chi-square test revealed that there are no significant differences in the prevalence of condylar erosions between sexes ( $p = 0.383$ ). This contrasts with what was reported by Vasegh Z et al.<sup>16</sup> (2023), who evaluated TMJ changes and found statistically significant differences between sex and the presence of condylar erosions ( $p = 0.001$ ).

Other authors, such as Barrera P, et al.<sup>17</sup> (2017), observed that in their study, 24% of men presented right-side flattening, while women accounted for 48.2% ( $p = 0.002$ ). On the left side, the authors reported that only 20% of men presented flattening, with women predominating at 42.1% ( $p = 0.004$ ). These results differ from the percentage distribution observed in this study, where women, although representing minority percentages, showed slightly higher proportions than men. Only 1.5% of men presented right-side condylar flattening and 1.8% left-side flattening.

Regarding age, Emshoff R et al.<sup>5</sup> (2021) reported a mean age of 40.1 years in the group of patients without condylar erosion and 32.8 years in the group with condylar erosion ( $p = 0.003$ ). These results partially agree with those observed in this study, where patients with condylar erosions had a similar mean age (38.48). The mean age observed in this study within the group of patients without condylar erosions was lower compared to that reported by the authors.

In another study, Rudiger E, et al.<sup>7</sup> (2021) reported a mean age of 36.6 years in patients without erosion and 39 years in patients with erosion. These authors indicated a lack of statistical significance between these variables ( $p = 0.174$ ), contrasting with what was observed in this study, where a highly significant  $p$ -value was obtained ( $p = 0.001$ ).

Jeon K et al.<sup>10</sup> (2021), on the other hand, reported that patients with condylar flattening had a mean age of 26.33 years. These results differ from those observed in this study, where a higher mean age (34.45 years) was obtained among patients with condylar flattening (left side, right side, or bilateral). In another study, Koc N, et al.<sup>18</sup> (2020), reported a mean age of 38.95 years in patients with condylar flattening. The authors indicated that there was no significant difference between these variables ( $p = 0.212$ ), similar to what was observed in the present study.

## CONCLUSION

The results showed a higher frequency of bilateral flattening compared to unilateral flattening and condylar erosions, which were observed in a lower proportion within the studied sample. Additionally, a total absence of coexistence between both conditions was observed; that is, no cases were found in which flattening and erosions were present in the same patient. Finally, significant differences were observed between age and the prevalence of condylar erosions. These results highlight the importance of considering age as a determining factor in the increase of condylar erosions, reinforcing the need to comprehensively evaluate TMJ conditions, especially in older populations.

## RECOMMENDATIONS

It is recommended to conduct a study to evaluate other factors that may be related to the presence of condylar flattening and erosions, such as malocclusions and parafunctional habits, in addition to variables such as stress and anxiety levels. It is also recommended to conduct research incorporating more advanced imaging techniques for evaluation, such as Cone Beam Computed Tomography (CBCT), to improve diagnostic accuracy.

## REFERENCES

1. Gharge, Nikhil R., S Ashwinirani and Abhijeet R Sande. "Comparison of temporomandibular changes in edentulous and dentulous patients using digital panoramic imaging." *Journal of Oral Research and Review*. 2020;12:17-22. [https://doi.org/10.4103/jorr.jorr\\_18\\_19](https://doi.org/10.4103/jorr.jorr_18_19)
2. Wojciechowska B, Szarmach A, Michcik A, Wach T, Drogoszewska B. Association between Clinical Manifestations in Temporomandibular Joint Disorders and Corresponding Radiographic Findings. *J Clin Med*. 2024;13(16):4886. <https://doi.org/10.3390/jcm13164886>
3. Kurnia SI, Himawan LS, Tanti I, Odang RW. Correlation between Chewing Preference and Condylar Asymmetry in Patients with Temporomandibular Disorders. *Journal of Physics: Conference Series*. 2018;1073(3):032014. <https://iopscience.iop.org/article/10.1088/1742-6596/1073/3/032014>
4. C Chung MK, Wang S, Alshantqi I, Hu J, Ro JY. The degeneration-pain relationship in the temporomandibular joint: Current understandings and rodent models. *Front Pain Res (Lausanne)*. 2023;4:1038808. <https://doi.org/10.3389/fpain.2023.1038808>
5. Emshoff R, Bertram A, Hupp L, Rudisch A. Condylar erosion is predictive of painful closed lock of the temporomandibular joint: a magnetic resonance imaging study. *Head Face Med*. 2021;17(1):40. <https://doi.org/10.1186/s13005-021-00291-1>
6. Cantor-Mora A, Fiori-Chíncaro GA. Evaluación del aplanamiento condilar en pacientes dentados y no dentados mediante radiografía panorámica. *Rev Cient Odontol (Lima)*. 2020; 8(1): e006. <https://doi.org/10.21142/2523-2754-0801-2020-006>
7. Emshoff R, Bertram A, Hupp L, Rudisch A. A logistic analysis prediction model of TMJ condylar erosion in patients with TMJ arthralgia. *BMC Oral Health*. 2021;21(1):374. <https://doi.org/10.1186/s12903-021-01687-w>
8. Oliveira DFLM, Fernandes EE, Lopes SLPC, Rode SM, Oliveira W, Ertty E, Cardoso MA, Tien-Li A, Meloti F. Prevalence of condylar morphological changes in individuals with class II malocclusion. *Braz Oral Res*. 2024;38:e060. <https://doi.org/10.1590/1807-3107bor-2024.vol38.0060>
9. Arayasantiparb R, Mitirattanakul S, Kunasarapun P, Chutimataewin H, Netnoparat P, Sae-Heng W. Association of radiographic and clinical findings in patients with temporomandibular joints osseous alteration. *Clin Oral Investig*. 2020;24(1):221-227. <https://doi.org/10.1007/s00784-019-02945-6>
10. Jeon KJ, Lee C, Choi YJ, Han SS. Analysis of three-dimensional imaging findings and clinical symptoms in patients with temporomandibular joint disorders. *Quant Imaging Med Surg*. 2021;11(5):1921-1931. <https://doi.org/10.21037/qims-20-857>
11. Cömert Kiliç S, Kiliç N, Sümbüllü MA. Temporomandibular joint osteoarthritis: cone beam computed tomography findings, clinical features, and correlations. *Int J Oral Maxillofac Surg*. 2015;44(10):1268-74. <https://doi.org/10.1016/j.ijom.2015.06.023>
12. Rodríguez López AKY, Valdez Palomino DJ. Estudio radiográfico de las alteraciones morfológicas de cóndilos mandibulares en una población adulta de Piura – Perú, 2017 – 2019. *Repos Inst - UCV*. 2020; Disponible en: <https://repositorio.ucv.edu.pe/handle/20.500.12692/62837>
13. Bae S, Park MS, Han JW, Kim YJ. Correlation between pain and degenerative bony changes on cone-beam computed tomography images of temporomandibular joints. *Maxillofac Plast Reconstr Surg*. 2017;39(1):19. <https://doi.org/10.1186/s40902-017-0117-1>
14. Jung W, Lee K, Suh B. Comparison of Clinical and Radiological Characteristics of Temporomandibular Joint Osteoarthritis in Older and Young people . *Open Dent J*. 2022;16: e187421062112290. <http://dx.doi.org/10.2174/18742106-v16-e2112290>
15. Zhou J, Yang H, Li Q, Li W, Liu Y. Comparison of temporomandibular joints in relation to ages and vertical facial types in skeletal class II female patients: a multiple-cross-sectional study. *BMC Oral Health*. 2024;24(1):467. <https://doi.org/10.1186/s12903-024-04219-4>.
16. Vasegh Z, Safi Y, Azar MS, Ahsaie MG, Arianezhad SM. Assessment of bony changes in temporomandibular joint in patients using cone beam computed tomography - a cross sectional study. *Head Face Med*. 2023;19(1):47. <https://doi.org/10.1186/s13005-023-00392-z>
17. Canales, Patricio. Cofré, José. Collio, William. Descripción morfológica de la articulación temporomandibular observada en imágenes cone beam de un grupo de pacientes entre 8 y 83 años de la ciudad De Santiago, Chile. *ResearchGate*. Disponible en: <https://doi.org/10.13140/RG.2.2.19147.23847>
18. Koç N. Evaluation of osteoarthritic changes in the temporomandibular joint and their correlations with age: A retrospective CBCT study. *Dent Med Probl*. 2020;57(1):67-72. <https://doi.org/10.17219/dmp/112392>

**AUTHOR CONTRIBUTION STATEMENT**

*“Conceptualization and design: Ávila Aguirre Christian, Diaz Rojas Dennisse; Literature review: Diaz Rojas Nicole; Methodology and validation: Ávila Aguirre Christian, Diaz Rojas Dennisse; Formal analysis: Diaz Rojas Nicole; Investigation and data collection: Ávila Aguirre Christian, Diaz Rojas Dennisse, Diaz Rojas Nicole; Resources: Not applicable; Data analysis and interpretation: Ávila Aguirre Christian, Diaz Rojas Dennisse; Writing – original draft preparation: Ávila Aguirre Christian; Writing – review and editing: Ávila Aguirre Christian, Diaz Rojas Dennisse; Supervision: Diaz Rojas Dennisse; Project administration: Diaz Rojas Dennisse; Funding acquisition: Not applicable.”*

**CONFLICTS OF INTEREST**

*The authors declare that there were no conflicts of interest during the conduct of this research. In addition, the manuscript was submitted exclusively to the Revista Científica “Especialidades Odontológicas UG” for review and publication.*

**FUNDING**

*The authors report that personal funds were used to carry out this research.*

**HOW TO CITE:**

*Avila Aguirre CS, Diaz Rojas DF, Diaz Rojas NF. Conventional radiographic analysis of facet joint and condylar erosion in patients at the UCSG. Prevalence study. Revista Científica Especialidades Odontológicas UG. 2026;9(1):22-8.*